

# Ashwini Hospital & Pathology Laboratory

Ground Floor, Gulmohar Centre Point, Pune Nagar Rd

Pune 411014

Tel: 020-4056456, 26754328, Email: info@ashwinihosp.com

NAME : MR. Raj Awiv

AGE : 22 YEARS

SEX : Male

REF BY : Dr Samir gupta

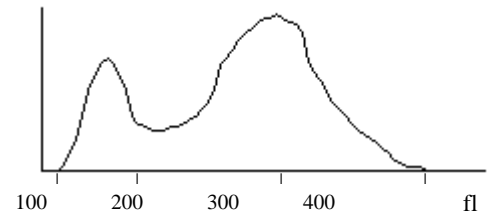
REG NO. : OPD / 5

DATE : 30/12/2008

## COMPLETE BLOOD COUNT

<u>TESTS</u>	<u>RESULTS</u>	<u>UNITS</u>	<u>REF RANGE</u>
Haemoglobin	: 11.2	gm%	14 - 18
R.B.C. count	: 3.09	mil./cmm.	4.5 - 6.5
Total WBC Count	: 11000	/cmm	4000 - 11000
Platelet	: 9.11	lakhs/cmm	1.5 - 4.5
Reticulocyte Count	: 0.5	%	0.5 - 1.5
ESR (Wintrobe)	: 10	mm/hr	0 - 15
Lymphocyte Count	: 2700	/cmm	2000 - 4500
Granulocyte Count	: 7200	/cmm	4000 - 7500
MID Count	: 1100	/cmm	100 - 1000

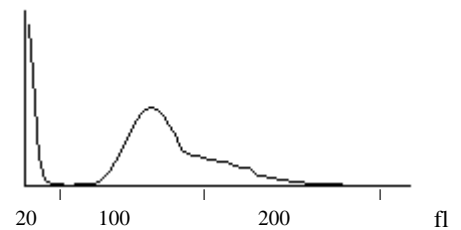
WBC HISTOGRAM



## RED CELL ABSOLUTE VALUES

Packed Cell Volume	: 36.9	%	35 - 47
Mean Corpuscular Volume	: 96.7	cu micron	76 - 96
MCH	: 36.4	picograms	27 - 32
MCHC	: 37.6	g/dl	32 - 36
RDW <sub>a</sub>	: 36	fl	35 - 56
RDW-CV	: 14.4	%	

RBC HISTOGRAM



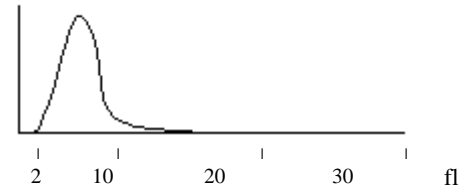
## PLATELET ABSOLUTE VALUES

PLCR	: 1.9	%	
MPV	: 4.6	fl	
PDW	: 6.5	fl	
PCT	: 0.42	%	

## DIFFERENTIAL COUNT

Neutrophils	: 65.4	%	40 - 70
Lymphocytes	: 24.8	%	20 - 45
Eosinophil	: 5	%	0 - 6
Monocytes	: 4.8	%	0 - 8
Basophils	: 0	%	0 - 1

PLT HISTOGRAM



## PERIPHERAL SMEAR EXAMINATION

Erythrocytes	: Normocytic normochromic with a few microcytic hypochromic rbes. Mild anisopoikiloytosis is seen. No immature erythroid series cells. No parasites.
Lucocytes	: Normal in number, predominant cells are neutrophils. No immature cells or a typical cells seen.
Platelets	: Adequate in number and seen in good clumps
Parasites	: Not detected
Absolute Eosinophil Count	: 110 cells/cmm 40 - 440
IMPRESSION	: Normocytic Normochromic Anaemia

Dr. Chavan V.B.

MD (Path)