

Jyoti Hospital & Pathology Laboratory

223, Gulmohar center point

Pune Nagar Rd, Pune 411014, Tel. 26635859, 56027856

Lab Timings: 8.00 A.M. to 8.00 P.M., Sunday Closed

Email: infojyoti@rediffmail.com

HPE No.	: B/3/2005	OPD/IPD No	: 3/2005	Date	: 19/06/2005
Name	: Mrs. Rita Bhaduri	Age	: 35 Years	Sex	: Female
Dept	: Obs & Gynae	Ward	: General	Bed No	: 23
Referred by	: Ramalayan Hospital				

Biopsy Report

Specimen : Multiple bits of tissue received

Gross Examination :

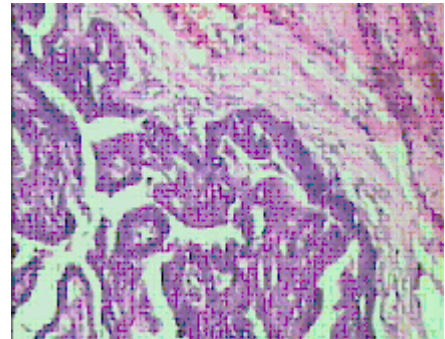
Speciman consists of uterus and cervix measuring about 10.8x 6.4 x 5.5cm.

Externally greyish white in colour with globular appearance.

c/s shows 0.2 mm thick endometrial layer .

Both the tubes are distended with lumen showing brownish haemorrhages(hematosalpinx).

Rt. ovary shows haemorrhagic cyst on c./s.



Microscopic Examination :

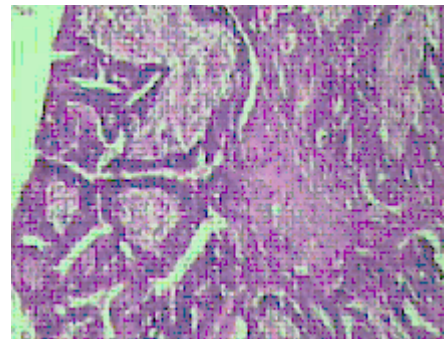
Endometrium shows cystic proliferative hyperplasia. Stroma is compact. Myometrium shows foci of adenomyosis.

Cervix = Ectocervical lining shows mild hyperplasia. Few of the endocervical glands show cystic dilatation. Subepithelial stroma shows moderate lymphocytic infiltrate with congested vessels.

Both the tubes show haemorrhages in the lumen.

Rt. ovary shows haemorrhagic corpus luteal cyst.

Lt. ovary shows atretic follicles amongst congested stroma.

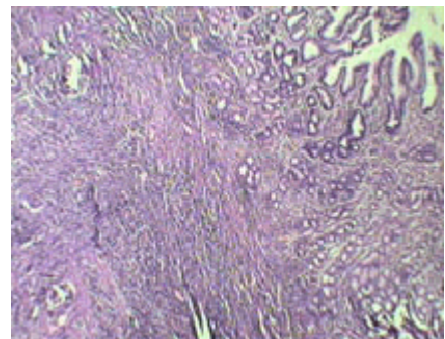


Opinion :

Endometrium shows cystic proliferative hyperplasia

Cervix shows chronic nonspecific cervicitis.

There is no evidence of malignancy.



Dr. Atul Nayak
M.D. (Pathology)